


# Ultrahigh Risk Gestational Trophoblastic Neoplasia (GTN) with Lung, Liver and Brain Metastasis: A Case Study Depicting Diagnostic Dilemma and Clinical Challenges of Management


Kar Bijoy<sup>1</sup>, Dave Pariseema S<sup>2</sup>, Patel Bijal M<sup>3</sup>, Parekh Chetana<sup>4</sup>  
Lecturer<sup>1</sup>, Professor<sup>2</sup>, Professor and Head of Unit<sup>3</sup>, Associate Professor<sup>4</sup>  
Department of Gynecologic Oncology


The Gujarat Research Cancer & Research Institute, Asarwa, Ahmedabad, Gujarat, India

Corresponding author: pariseema.dave@gcri.org

 <sup>1</sup><https://orcid.org/0000-0001-6176-8687>

 <sup>2</sup><https://orcid.org/0000-0003-3300-4414>

 <sup>3</sup><https://orcid.org/0000-0002-5446-1959>

 <sup>4</sup><https://orcid.org/0000-0003-4811-5889>

## Summary

A 27 year young lady with recent history of molar pregnancy referred from outside as a case of suspected astrocytoma of brain and was finally diagnosed as a case of ultrahigh risk Gestational Trophoblastic Neoplasia (GTN) stage IV (brain, liver, lung metastasis) with risk Score 14. Patient received whole brain radiotherapy (WBRT) + Triple intra thecal (IT) therapy followed by 2 cycles of Etoposide and Cisplatin (EP), 9 cycles of EMA-CO, 4 cycles of EP-EMA. Again patient had risen of  $\beta$  hCG for which she received 6 cycles of VeIP. Patient is having persistently low  $\beta$  hCG for last 2 years. Multiple regimens of chemotherapy and multidisciplinary team effort were the key factor for success of this ultrahigh risk patient GTN patient management.

**Key words:** FIGO -The International Federation of Gynecology and Obstetrics, VeIP- vinblastine, ifosfamide, cisplatin, hCG – Human Chorionic Gonadotropin, CSF- Cerebrospinal fluid.

## Introduction

GTN is described as “God’s first cancer and man’s first cure”, refers to spectrum of malignant trophoblastic disease comprising invasive mole, Choriocarcinoma, Placental site trophoblastic tumor (PSTT) and epitheloid trophoblastic tumor (ETT). GTN patient with the FIGO score <7 is low risk, score  $\geq 7$  is high risk and  $\geq 12$  is defined as ultrahigh-risk GTN and it carries poor prognosis.<sup>1</sup> There is a high likelihood of resistance to first line chemotherapy, hence optimal therapy is controversial.<sup>2</sup> Here, we have selected the case as it gave us the insight to confront the different challenges, complications and learning we came across related to ultrahigh stage GTN with multi organ metastasis.

## Case

A 27 years lady para 1 live 1 with 1 abortion 6 months back presented with astrocytoma of brain on June 2017 in our institute. At admission complaint was vomiting, headache and paraplegia. On past obstetric history and scrutiny of old documents revealed that she had suction and evacuation for molar pregnancy abortion and she was followed up with serum  $\beta$  hCG

outside but it never touched the normal level. CT scan shows multiple brain metastatic lesion in left occipital region (largest 2.2 cm) with peri-lesional oedema, 2 lung metastasis and liver metastasis. At admission her serum  $\beta$  hCG was 5,17,694 IU/L, CSF  $\beta$  hCG- 2855.0 IU/L. On evaluation WHO prognostic score was 14 and FIGO stage IV. Initially she was treated in ICU with mannitol, phenytoin, blood transfusion, electrolyte correction and other supportive measures. Multi-disciplinary tumor board was conducted and started with whole brain radiotherapy (WBRT) 30 Gray 10 fractions followed by intra thecal (IT), triple chemotherapy (MTX, cytarabine, hydrocortisone). As etoposide, methotrexate, actinomycin, cyclophosphamide, vincristine (EMACO) cannot be given with WBRT and etoposide, cisplatin (EP) will be toxic with RT hence, interim biweekly triple IT was given in view of WBRT induced initial rise of  $\beta$  hCG.

Thereafter 9 cycles of EMACO and 2 cycles of EP (low dose) received through internal jugular vein chemo port till 29<sup>th</sup> November 2017. At the completion her serum  $\beta$  hCG came down to 7.8 IU/L. Patient required intermittent G-CSF injection for neutropenia. Due to rise in hCG 4 cycles of EMA- EP was given till 14<sup>th</sup> February 2018. Patient developed herpes labialis, low ANC. Due to poor tolerance of chemo dense therapy and stable  $\beta$  hCG (plateau at 5.5 IU/L) in near complete remission range decision was made to no further chemotherapy and closely observe the patient with every week serum  $\beta$  hCG monitoring. On 25<sup>th</sup> April 2018 there was rise in serum  $\beta$  hCG from 10.47 IU/L (previous) to 131.0 IU/L within a week. On 1<sup>st</sup> May serum  $\beta$  hCG came 461.0 IU/L. PET CT showed 3.5x3.2 lesion in posterior wall of uterus, multiple well defined opacities in the both lung field, 1.3x1 cm hypo dense lesion with peripheral enhancement in left occipital region with no appreciable uptake. Vinblastine, ifosfamide, cisplatin (VeIP) chemotherapy started. After 3<sup>rd</sup> cycle VeIP  $\beta$  hCG normalized and thereafter 3 more cycles of VeIP continued till 10<sup>th</sup> October 2018.

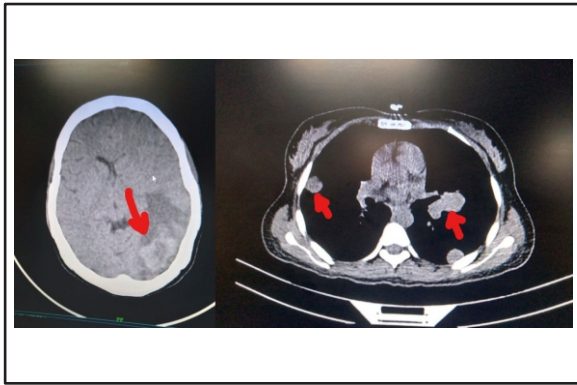


Figure 1: Brain and liver metastasis

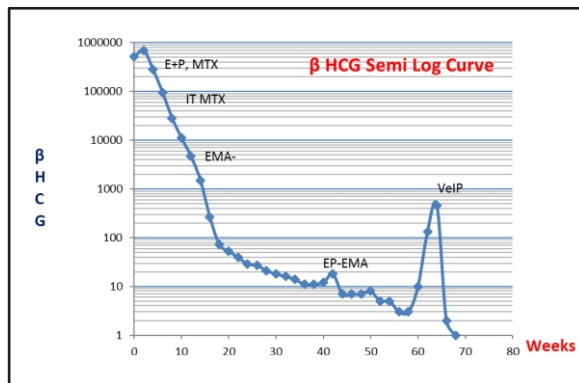


Figure 2: Multiple chemotherapy induced  $\beta$  hCG regression curve

Following 6<sup>th</sup> cycle of VeIP CT scan was done which revealed 1.3 cm hypo dense lesion in posterior wall of uterus, 0.9 cm soft tissue opacities in bilateral lung field- suggestive of responding of disease. Clinical examination was normal except bulky uterus. Patient is in follow up in stable condition with persistently normal serum  $\beta$  hCG of 0.1 IU/L for last 2 years.

### Discussion

Although GTN is thought to be highly chemo-sensitive tumor with very good prognosis, same may not be always true for ultrahigh risk GTN with brain and liver metastasis. Ultrahigh risk GTN particularly with non-molar antecedent pregnancy, brain metastases, and previous multi-agent chemotherapy failure are poor prognostic factor.

It has been seen that induction with low dose EP has may reduce the early mortality. EMA/CO can still be considered as effective regimen and manageable toxicities for most of the patients with ultrahigh risk GTN.<sup>3</sup> EP-EMA regimen is used in patients who experienced relapse or became refractory to EMA-CO treatment.<sup>4</sup> In patient with brain metastasis may require WBRT and/or IT methotrexate (MTX). Salvage surgeries like hepatic resection, arterial embolization, stereotactic radiosurgery of cerebral metastasis, thoracotomy may improve prognosis. Recent studies has shown that PD1 inhibitors like Pembrolizumab can be one of the option to treat multi drug resistant ultrahigh risk GTN but needs more data to establish it as a standard treatment.<sup>5</sup>

In our case young patient with a small child having GTN stage IV, WHO score 14 with liver, lung, brain metastasis was not only traumatizing to the family but it was a clinical challenge also. At first diagnose the case as Astrocytoma by outside Neurophysician just depending upon her neurological symptoms and brain imaging created confusion. Here lies the importance of obstetric and gynecologic history for every woman otherwise recent history of molar pregnancy abortion would have guided towards GTN from the time of presentation. Multidisciplinary team work, good patient compliance, family and financial support which are the cornerstone for long duration of successful treatment.

### Conclusion

Every case of ultrahigh risk of GTN is unique and very demanding - requiring individual patient treatment plan according to the clinical scenario and disease distribution. For each such patient the treating onco-physician needs some extra devotion to the patient and very close monitoring to combat the complications at the earliest. Sometimes multiple chemo resistant or refractory cases may warrant to even use some experimental treatment regimen. As there is no standard treatment for ultrahigh stage of GTN for rarity of the disease incidence; there should be multi centric international patient database and clinical study to establish evidence based management protocol in near future.

### Conflict of Interest

Patient's consent was procured. There is no conflict of interest for publication of this case report.

### References

1. Kong Y, Yang J, Jiang F et al: Clinical characteristics and prognosis of ultrahigh-risk gestational trophoblastic neoplasia patients: a retrospective cohort study. *Gynecologic Oncology* 2017;146:81-86
2. Oranratanaphan S, Lertkhachonsuk R: Treatment of extremely high risk and resistant gestational trophoblastic neoplasia patients in King Chulalongkorn Memorial Hospital. *Asian Pacific Journal of Cancer Prevention* 2014;15:925-928
3. Shen T, Chen LL, Qin JL et al: EMA/CO regimen for chemotherapy 24 patients with ultrahigh-risk gestational trophoblastic neoplasia. *Zhonghua fu Chan ke za zhi* 2018;53:371-376
4. Mao Y, Wan X, Lv W et al: Relapsed or refractory gestational trophoblastic neoplasia treated with the etoposide and cisplatin/etoposide, methotrexate, and dactinomycin D (EP-EMA) regimen. *International Journal of Gynecology & Obstetrics* 2007;98:44-47
5. Cheng HY, Yang JJ, Zhao J et al: Preliminary study of PD-1 inhibitor in the treatment of drug-resistant recurrent gestational trophoblastic neoplasia. *Zhonghua fu Chan ke za zhi* 2020;55:390-394